

# Optical Coherence Tomography for studies of the larynx mucosa in the arytenoids regions

## A protocol



M. Pedersen  
Ear-, Nose-, Throat specialist  
FRSM Dr.med.Sci. et h.c.

Anne B. Alexius Agersted  
Stud. Medicine  
University of Copenhagen

The Medical Center, ear nose throat unit.  
Oestergade 18, DK-1100 Copenhagen, Denmark  
Phone: +45 33137700, +45 33159600  
Mobile: +45 31126184, Fax: +45 33137705  
E-mail: [m.f.pedersen@dadlnet.dk](mailto:m.f.pedersen@dadlnet.dk)  
Url// [www.mpedersen.org](http://www.mpedersen.org)

### Background

#### Definition

Optical coherence tomography (OCT) is an imaging technology that provides cross-sectional images of subsurface tissue structure at approximately 10 µm resolution to a depth of 1,5 mm using backscattered light. OCT has shown promise in imaging normal vocal folds as well as various laryngeal disorders. The use of OCT to image the larynx during diagnosis and treatment of a vast array of laryngeal disorders continues to develop along with innovative surgical techniques. An augmented form of OCT polarization-sensitive OCT (PS-OCT) is creating useful clinical applications for diagnostic and therapeutic laryngeal procedures.

#### Causality

In a prospective cohort study partial cure of dystonia was found, where the mode of treatment was fexofenadine tablets and local budesonide inhaler in the larynx, and in a randomized controlled trial of lifestyle change related to acid provocation of food and habits were essential in laryngopharyngeal reflux (LPR). The advanced high-speed films is one new tool with exact pictures of the moving larynx including the arytenoid region, another being OCT, they should be used further in the future in randomized controlled trials.

We are focusing on OCT of the swallowing process in the esophagus and larynx, as well as the vocal fold function. It can be shown on OCT how the layer of the vocal folds develop, possibly corresponding to hormonal and pediatric development. The arytenoid area layers in the larynx should also be focused upon with OCT in pathology. The thyroid function is related to voice and the swallowing function, both hormonally and anatomically. We know too little about voice and thyroid hormones in an updated way as well as the outer anatomic supporting structure of the larynx, among others related to thyroid immune degeneration and cysts. The combined high speed films and OCT could give much more information of pathology of the layers of the larynx.

### Objectives

We want to determine whether OCT is ready for evaluating edema of the arytenoid region, or further work to improve the OCT has to be done before this is possible. Furthermore, if this method is applicable, it would be interesting to see if the visual arytenoid edema grading system (1-5) could be quantified for further research of mucosal barrier health.

### Criteria for considering patients for the study

#### Types of participants

All adult (aged 18 or over) patients with hoarseness (dysphonia). The participants should have had the symptom for at least six weeks. The participants will be included whether or not there is a definitive diagnosis. All patients should have undergone laryngoscopy to exclude other identifiable causes of hoarseness including malignancy, and vocal cord paralysis.

### Types of intervention

#### Laryngopharyngeal reflux

- 1) Pharmacological treatment. Proton pump inhibitors (PPIs)
- 2) Lifestyle modification and patient education

#### Allergy treatment

- 1) Removal of provocations
- 2) Fexofenadine 1-2 tablets a day of 180 mg and budesonide inhaler.

#### Infections in the larynx

- 1) Azitromycin 500 mg a day for 6 days
- 2) Secondary antibiotic based on swabs with micro pathological advice

#### Dystonia and hoarseness

- 1) Fexofenadine 180 mg x 2-3 daily budesonide 160 micrograms 2-3 times a day

### Types of outcome measures

#### The following outcomes will be assessed:

##### (1) Subjective complains of

- Hoarseness or a problem with your voice
- Clearing your throat/excess throat mucus or postnasal drip
- Difficulty swallowing food, liquids, or pills (dysphagia)
- Coughing after you ate or after lying down, troublesome or annoying cough
- Breathing difficulties or choking episodes (larynx spasms and hick ups)
- Sensations of something sticking in your throat or a lump in your throat (globules)

##### (2) High speed films of the larynx, visual scores 1-5 of the arytenoid regions (see Figure 1) with

- Kymograms
- Glottal openings kvotient
- Electroglottograms
- Segmentations

##### (3) Out measures include 'objective' findings of laryngeal appearance on OCT.

### Arythenoid oedema

Figure 1: In our Cochrane review of laryngopharyngeal reflux considerations were made of the function of the arytenoid region. We have also tried to define visual scores (1-5) of the oedema, and compared the visual scores to voice pathology.

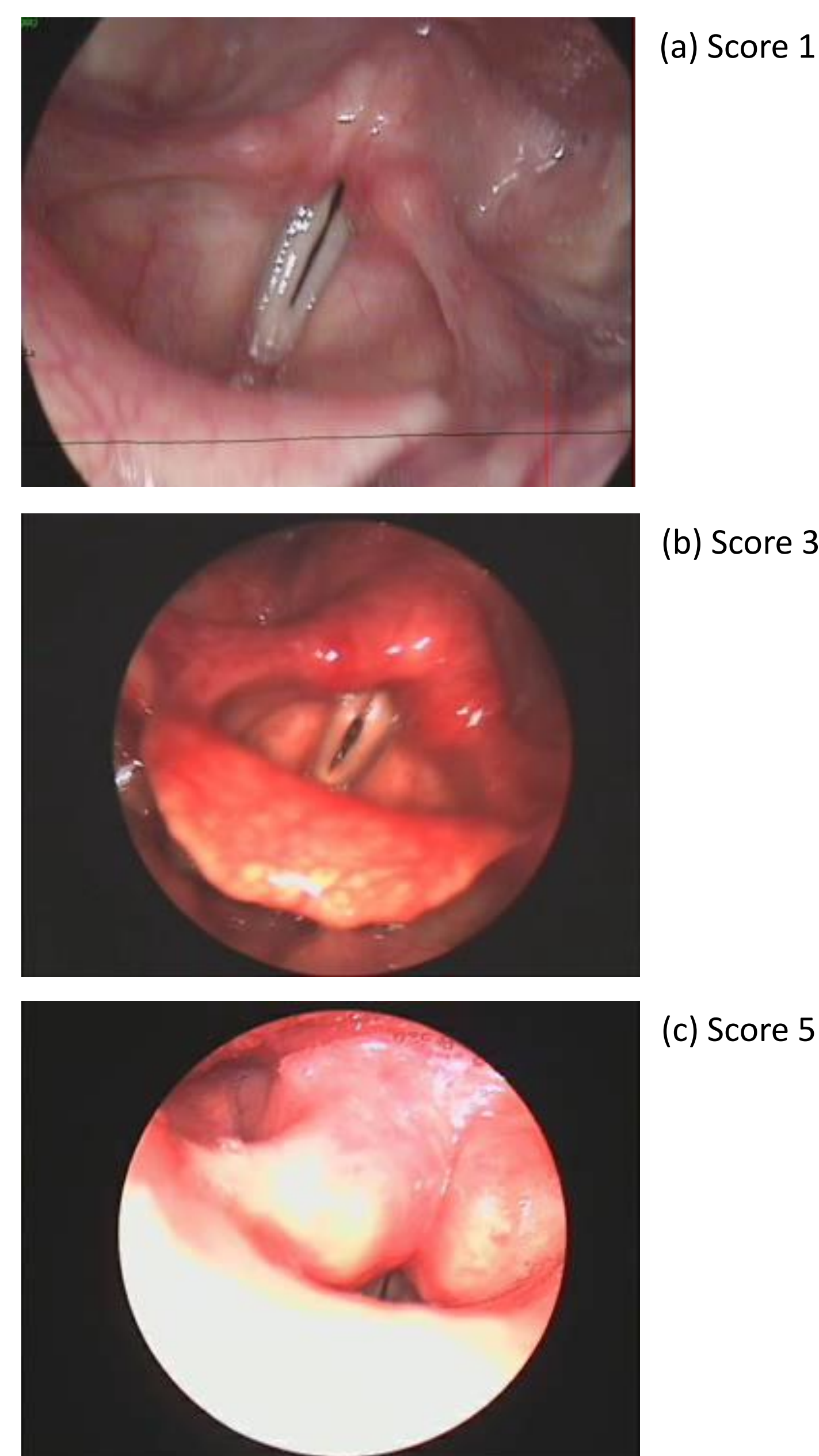


Figure 1: High-speed films scores with 4,000 pictures per second of the larynx including the arytenoid regions. Score 1 is a normal arytenoid region. Score 3 is presenting a moderate oedema. Score 5 is almost total closure of the larynx due to arytenoid oedema (3).

### OCT images with corresponding histology

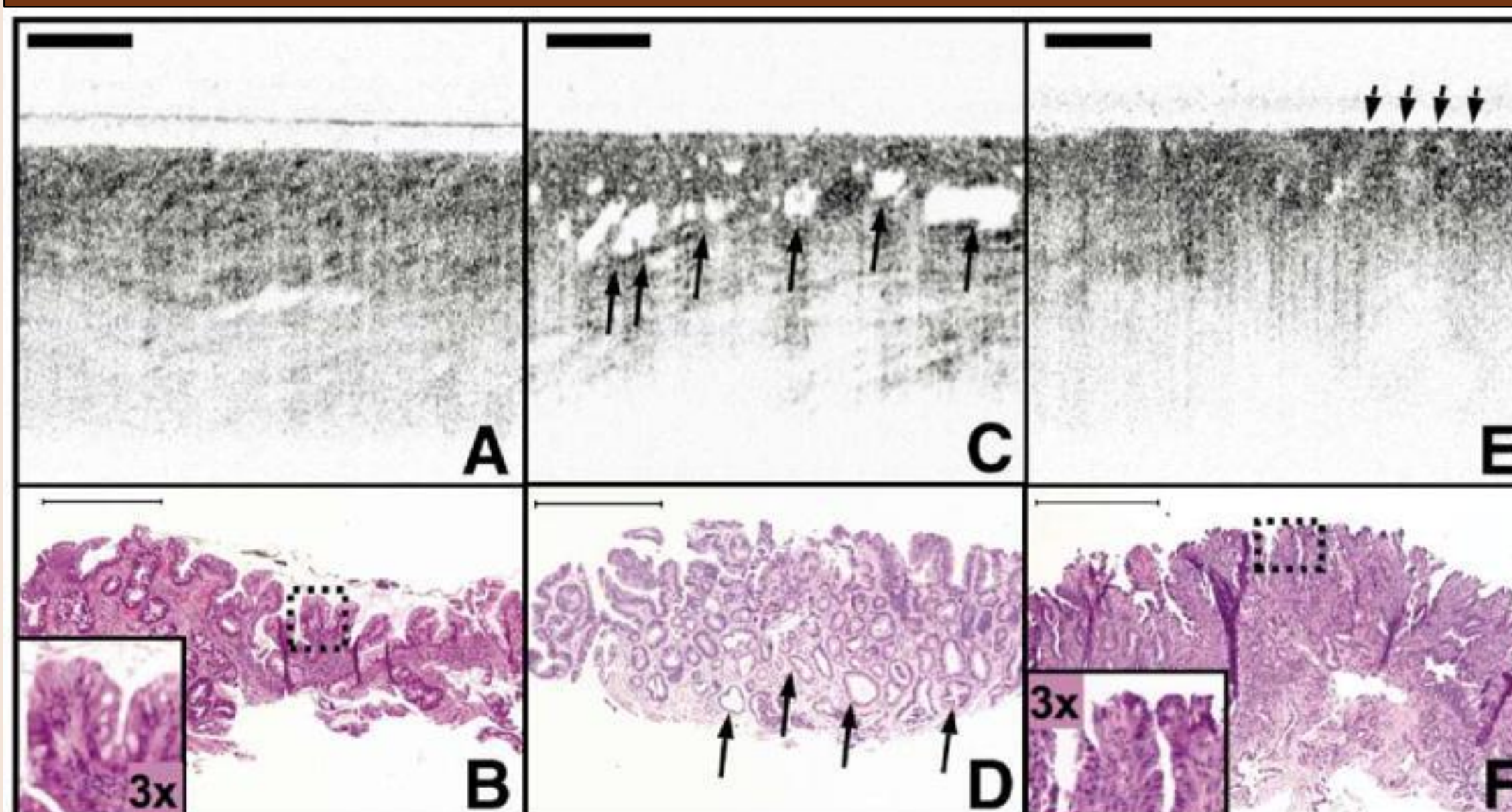


Figure 2: OCT images of SIM with and without IMC/HGD. (A) OCT image of SIM without dysplasia demonstrates glandular architecture with a relatively low reflectivity. (B) Corresponding histology to (A) with inset demonstrates a low nuclear to cytoplasm ratio in the superficial epithelium. (C) OCT image of IMC/HGD enables visualization of large and irregular glands (arrows). (D) Irregular, dilated glands are also seen in the corresponding histology to (C) (arrows). (E) OCT image of IMC/HGD shows a disorganized architecture and increased surface reflectivity (arrows). (F) Corresponding histology for (E) demonstrates abnormal glandular architecture and an increased superficial nuclear to cytoplasm ratio (inset). Histology: hematoxylin-eosin; original magnification, 40 x. Scale bars, 500 µm

With permission from NIH Public Access. Clin Gastroenterol Hepatol. Hepatol. 2006; 4:38-43.

### Studies leading to this protocol

Hopkins C, Yousaf U Pedersen M (2006) Acid reflux treatment for hoarseness (review).  
The Cochrane library Oxford. Wiley publishing. Issue 2.

Pedersen M, Munck K (2007) A prospective case-control study of jitter% shimmer% and Qx%, glottis closure, cohesion factor and Longtime average spectra. (Speed program by Laryngograph Ltd.)  
Models and analysis of vocal emissions for biomedical applications (MAVEBA) pp 60-64.

Pedersen M, McGlashan J (2012) Surgical versus non-surgical intervention for vocal cord nodules (review).  
The Cochrane library update Oxford. Wiley publishing.

Pedersen M, Eeg M (2012) Laryngopharyngeal reflux – a randomized clinical controlled trial.  
Otolaryngology, Omnicis publishing group. St:004.doi:10.4172/2161-119X

Pedersen M, Eeg M (2012) Does treatment of the laryngeal mucosa reduce dystonic symptoms? A prospective clinical cohort study of mannose binding lectin and other immunological parameters with diagnostic use of phonatore function studies.  
European Archives of Otorhinolaryngology.269,5:1477-1482laryngeal mucosa reduce dystonic symptoms?

### References of OCT

1. Pedersen M, (2014), Future aspects of cellular and molecular research, *Advances in Cellular and Molecular Otolaryngology*; 2:24442.
2. Just T, Lankenau E, Prall F, et. al. (2010), Optical coherence tomography allows for the reliable identification of laryngeal epithelial dysplasia and for precise biopsy: A clinicopathological study of 61 patients undergoing microlaryngoscopy, *Laryngoscope*; 120(10):1964-70. doi: 10.1002/lary.21057.
3. OPMedt, intraoperative OCT, <http://www.opmedt.com/index.php/en/intraoperative-oct-eng/intraoperative-oct-in-ent>
4. Just T, Lankenau E, Hüttmann G, et. al. (2009), Intraoperative OCT application with an operating microscope, *Laryngology & Otolaryngology*; 123:1027-1030. Doi:10.1017/S0022215109004770.
5. Olzowy B, Starke N, Schuldt T, et. al. (2013), Optical coherence tomography and confocal endomicroscopy for rhinologic pathologies: a pilot study, *Biomed Opt*; 880505.
6. Tearney GJ, Regar E, Akasaka T, et. al. (2012), Consensus standards for acquisition, measurements, and reporting of intravascular optical coherence tomography studies: a report from the International Working Group for Intravascular Optical Coherence Tomography Standardization and Validation, *J Am Coll Cardiol*; 59(12):1058-72. doi: 10.1016/j.jacc.2011.09.079.
7. Jamil Z, Tearney G, Bruining N, et. al. (2013), Interstudy reproducibility of the second generation, Fourier domain optical coherence tomography in patients with coronary artery disease and comparison with intravascular ultrasound: a study applying automated contour detection, *Int J Cardiovasc Imaging*; 29(1):39-51. doi: 10.1007/s10554-012-0067-8.
8. Unglert CI, Warger WC, Hostens J, et. al. (2012), Validation of two-dimensional and three-dimensional measurements of subpleural alveolar size parameters by optical coherence tomography, *J Biomed Opt*; 17(12):126015. doi: 10.1117/1.JBO.17.12.126015.
9. Liu L, Chu KK, Houser GH, et. al. (2013), Method for quantitative study of airway functional microanatomy using micro-optical coherence tomography, *PLoS One*; 8(1):e54473. doi: 10.1371/journal.pone.0054473.
10. Hariri LP, Applegate MB, Mino-Kenudson M, et. al. (2013), Optical frequency domain imaging of ex vivo pulmonary resection specimens: obtaining one to one image to histopathology correlation, *J Vis Exp*; 22(71). pii:3855. doi: 10.3791/3855.
11. Saik J, Coron E, Kava L, et. al. (2013), Interobserver agreement for the detection of Barrett's esophagus with optical frequency domain imaging, *Dig Dis Sci*; 58(8):2261-5. doi: 10.1007/s10620-013-2625-x.
12. Schlett CL, Maurovich-Horvat P, Ferencik M, et. al. (2013), Histogram analysis of lipid-core plaques in coronary computed tomographic angiography: ex vivo validation against histology, *Invest Radiol*; 48(9):646-53. doi: 10.1097/RLI.0b013e31828fd9f9.
13. Hariri LP, Mino-Kenudson M, Applegate MB, et. al. (2013), Toward the guidance of transbronchial biopsy: identifying pulmonary nodules with optical coherence tomography, *Chest*; 144(4):1261-8. doi: 10.1378/chest.13-0534
14. Conti de Freitas LC, Phelan E, Liu L, et. al. (2013), Optical coherence tomography imaging during thyroid and parathyroid surgery: A novel system of tissue identification and differentiation to obviate tissue resection and frozen section, *Head Neck*; doi: 10.1002/hed.23452.
15. Fleming CO, Eckert J, Halpern EF, et. al. (2013), Depth resolved detection of lipid using spectroscopic optical coherence tomography, *Biomed Opt Express*; 5(4):1269-84. doi: 10.1364/BOE.5.001269.
16. Suter MJ, Gora MJ, Lauwers GY, et. al. (2014), Esophageal guided biopsy with volumetric laser endomicroscopy and laser cautery marking: a pilot clinical study, *Gastrointest Endosc*; 79(6):886-96. doi: 10.1016/j.gie.2013.11.016.
17. Birket SE, Chu KK, Liu L, et. al. (2014), A functional anatomic defect of the cystic fibrosis airway, *Am J Respir Crit Care Med*; doi: 10.1164/rccm.201404-0670OC.
18. Kirtane TS, Wagh MS, (2014), Endoscopic optical coherence tomography (OCT): Advances in gastrointestinal imaging, *Gastroenterol Res Pract*; 2014:376367. doi: 10.1155/2014/376367.
19. Oh WY, Yun SH, Vakoc BJ, et. al. (2008), High-speed polarization sensitive optical frequency domain imaging with frequency multiplexing, *Opt Express*; 16(2):1096-103.
20. Kim KH, Park BH, Maguluri, et. al. (2007), Two-axis magnetically-driven MEMS scanning catheter for endoscopic high-speed optical coherence tomography, *Opt Express*; 15(26):18130-40.
21. Pierce MC, Hyle PB, Cense B, et. al. (2002), Simultaneous intensity, birefringence, and flow measurements with high-speed fiber-based optical coherence tomography, *Opt Lett*; 27(17):1534-6.
22. Burns JA, Kim KH, deBoer JF, et. al. (2011), Polarization-sensitive optical coherence tomography imaging of benign and malignant laryngeal lesions: an in vivo study, *Otolaryngol Head Neck Surg*; 145(1):91-9. doi: 10.1177/0194599811403078.
23. Burns JA, Kim KH, Kobler JB, et. al. (2009), Real-time tracking of vocal fold injections with optical coherence tomography, *Laryngoscope*; 119(11):2182-6. doi: 10.1002/lary.20654.
24. Chang EW, Kobler JB, Yun SH, (2011), Triggered optical coherence tomography for capturing rapid periodic motion, *Sci Rep*; 2011;1:48. doi: 10.1038/srep00048.
25. Huang D, Swanson EA, Lin CP, et. al. (1991), Optical coherence tomography, *Science*; 22;254(5035):1178-81.
26. Duan C, Sun J, Samuelsen S, et. al. (2013), Probe alignment and design issues of microelectromechanical system based optical coherence tomography endoscopic imaging, *Appl Opt*; 52(26):6589-98. doi: 10.1364/AO.52.006589.
27. de Boer JF, Milner TE, (2002), Review of polarization sensitive optical coherence tomography and Stokes vector determination, *J. Biomed Opt*; 7(3):359-71.
28. Kobler JB, Chang EW, Zeitels SM, et. al. (2010), Dynamic imaging of vocal fold oscillation with four-dimensional optical coherence tomography, *Laryngoscope*; 120(7):1354-62. doi: 10.1002/lary.20938.
29. Liu G, Rubinstein M, Saidi A, et. al. (2011), Imaging vibrating vocal folds with a high speed 1050 nm swept source OCT and ODT, *Opt Express*; 19(12):11880-9. doi: 10.1364/OE.19.011880.
30. Burns JA, Zeitels SM, Anderson RR, et. al. (2005), Imaging the mucosa of the human vocal fold with optical coherence tomography, *Ann Otol Rhinol Laryngol*; 114(9):671-6.
31. Wijesundara K, Zdanski C, Kimbell J, et. al. (2014), Quantitative upper airway endoscopy with swept-source anatomical optical coherence tomography, *Biomed Opt Express*; 19;5(3):788-99. doi: 10.1364/BOE.5.000788.
32. Wong BJ, Jackson RP, Guo S, et. al. (2005), In vivo optical coherence tomography of the human larynx: normative and benign pathology in 82 patients, *Laryngoscope*; 115(11):1904-11.
33. Burns JA, (2012), Optical coherence tomography: imaging the larynx, *Curr Opin Otolaryngol Head Neck Surg*; 20:477-481. doi: 10.1097/MOO.0b013e318283582d7d.