

Optical Coherence Tomography in the laryngeal arytenoid mucosa for documentation of pharmacological treatments and genetic aspects. A protocol.

Mette Pedersen MD Hon. Prof. IBC Cambridge.
Sanila Mahmood (Stud. Pharm.), Anders Jønsson & Anne Agersted (Stud med.)

The Medical Center, ear nose throat unit.
Oestergade 18, Dk-1100 Copenhagen, Denmark., m.f.pedersen@dadlnet.dk
www.mpedersen.org

Abstract

- Background: **Optical Coherence Tomography (OCT)** is an imaging technology that provides cross sectional images of subsurface tissue structures also in the larynx without biopsy. Focus has till now been on the **vocal folds**. Since many kinds of mucosal disorders can be defined in the arytenoid regions behind the vocal folds and not on the vocal folds, we focus on this area in this protocol.
- Objective: A superficial oedema, grading 1-5 of the arytenoid regions, can be made with **high speed films of 4000 pictures/sec**. A supplementary larynx set-up with a **clinical probe for OCT** with across sectional measures can be made with description of levels of oedema and other parameters.
- Design: **Adult patients** with subjective **complaints of hoarseness or a problem in the larynx related to voice** and swallowing for more than 6 weeks in a randomised controlled study.
- Perspective and conclusion: **With this new OCT probe for the larynx arytenoid region, compared with high speed films, we will be able to define pathological areas in the arytenoid mucosa as a future documentation of pharmacological treatment and genetics related lifestyle advice.**

Introduction

- **Definition:**

Optical coherence tomography (OCT) is an imaging technology that provides cross sectional images without biopsy of subsurface tissue structure at approximately 10 μm resolution to a depth of 1,5 mm using backscattered light. OCT has shown promise in imaging normal vocal folds as well as various laryngeal disorders (1). The use of OCT to image the larynx during diagnosis and treatment of a vast array of laryngeal disorders continues to develop along with innovative surgical techniques. Monitoring the benign cellular and molecular events resulting in arytenoid oedema is of great interest. **There is a need to understand normal histology of the arytenoid region compared with disorders causing arytenoid oedema at the inflammatory process level.** The interesting thing is to find out whether it is related to infection, acid reflux or allergy. A long range OCT using Doppler optical coherence tomography is creating useful clinical applications for diagnostic and therapeutic laryngeal procedures on the vocal folds (1).

Introduction

- **Background:**

In a prospective cohort study partial cure of dystonia was found, where the mode of treatment was the **antihistamine, fexofenadine tablets and local cortisone (budesonide) inhaler** in the larynx with reduction of oedema of the arytenoid region as an objective finding (2a,2b). And in a randomized controlled trial of **lifestyle change** related to acid provocation, food and habits of sleep were essential in laryngopharyngeal reflux with hoarseness (LPR) treatment where treatment effect objectively was related to reduces oedema of the arytenoid regions (3), based on two Cochrane reviews showing lack of treatment evidence till now (4,5).

- **The advanced high-speed film is one new tool with exact pictures of the moving larynx including the arytenoid region, another could be OCT, they should be used together in future in randomized controlled trials.**

Introduction

- **Background:**

The swallowing process of the tissue in the upper oesophagus, does affect the voice control, especially for the nuanced registers stabilisation of the vocal fold function. The adductor muscles between the arytenoid cartilages cannot function efficiently and therefore hoarseness is often seen especially in the upper register.

It can be shown on OCT how the layers of the vocal folds develop, possibly corresponding to hormonal and paediatric development (6,7). The arytenoid area layers in the larynx have not been investigated with OCT in pathology. **The combined high speed films and OCT will certainly give much more information of pathology of the layers during voicing and swallowing. Till now, we have only had high speed films to look at the superficial arytenoid regions with 4000 pictures per second.** Of course we have many evidence based measures hereof that also could be compared to OCT (8,9). Sectional presentations of the arytenoid mucosa with OCT will in the future have enhanced value for diagnosis and treatment.

Objective

- The aim was to determine, based on the literature and our studies of high speed films, whether OCT with a laryngeal probe (1) is clinically feasible for evaluating oedema of the arytenoid region, in a stable way, or which kind of work should be made to improve the OCT probe before this is possible. Furthermore, if this method is applicable, it would be interesting to see if the visual arytenoid oedema grading system (1-5) could be the basis for further clinical quantified research of mucosal barriers in the upper airways, as it is done in dermatologic and eye background disorders with great success (1).

Design

- **Criteria for considering patients for the study**

Types of participants: **Adults (aged 18 or over) with hoarseness and complains of swallowing for more than 6 weeks** (dysphonia and laryngopharyngeal reflux). The participants should have had the symptoms for at least six weeks. The participants will be included whether or not there is a definitive diagnosis. All patients should **have undergone high speed video laryngoscopy** to exclude other identifiable causes of hoarseness including malignancy, and vocal fold paralysis. A prospective randomisation is accomplished with supplementary OCT in one half of the patient groups that includes at least 40 patients based on a power calculation of 5% difference of diagnosis evidence.

- **Types of intervention:**

Systematic treatment approach:

- Laryngopharyngeal reflux

- 1) Pharmacological treatment, proton pump inhibitors (PPI)
- 2) Lifestyle modification and patient education

- Allergy treatment

- 1) Removal of provocations of upper airways
- 2) Fexofenadine 1-2 tablets a day of 180 mg and budesonide inhaler.

- Infections in the larynx

- 1) Erythromycin (Azitromylin) 500 mg a day for 6 days
- 2) Secondary antibiotics based on swabs with medical micro-pathological advice

Design

- **The following outcomes will be assessed:**
- **Subjective complaints:**
Hoarseness in singing and speaking, or other problems with your voice, lack of high notes (hoarseness), clearing your throat/excess throat mucus or postnasal drip, **difficulty swallowing** food, liquids, or pills (dysphagia), **coughing** after you ate or after lying down, troublesome or annoying cough, **breathing difficulties**, choking episodes (larynx hick ups) and sensations of something sticking in your throat or a lump in your throat (globules).
- **High speed films of the larynx:**
Visual scores 1-5 of the arytenoid regions oedema (see Figure 1) with kymograms, glottal openings quotients, electroglottograms and segmentations (3,8,9).
- **Optical Coherence Tomography (OCT):**
Objective findings of laryngeal appearance on OCT images including histology related to cytoplasm in the superficial epithelium enables visualizing of large and irregular glands as well as oedema and expanding blood vessels. A disorganized architecture of the epithelium can be presented together with an increased nuclear to cytoplasm ratio.

Design

- Arytenoid oedema is presented in Figure 1
In our Cochrane review of laryngopharyngeal reflux considerations were made of the function of the arytenoid region and in our RCT these visual scores were valid (5,3): visual scores (1-5) of the oedema, compared to symptom complaints.

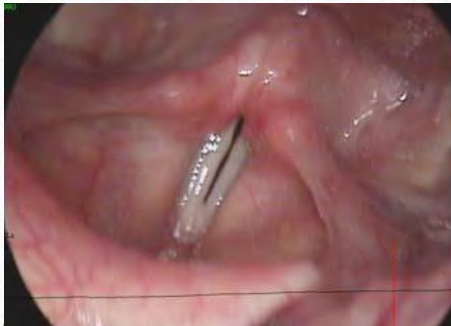

Fig. 1A
Score 1

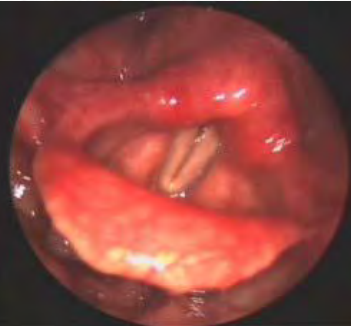

Fig. 1B
Score 3

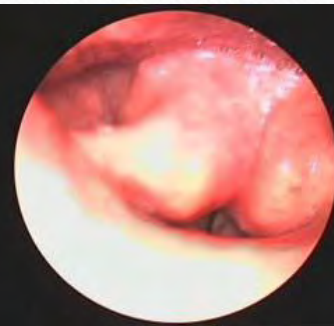

Fig. 1C
Score 5

Figure 1: High-speed films scores with 4,000 pictures per second of the larynx including the arytenoid regions. Score 1 is a normal arytenoid region and normal vocal folds. Score 3 is presenting a moderate oedema of the arytenoid region and normal vocal folds. Score 5 is almost total closure of the larynx due to arytenoid oedema (3).

Discussion

- As with other new methods the development evaluation includes apparatuses development – in this case a probe for the larynx - as well as documentation of clinical use at best in randomised prospective clinical trials. OCT images are well known on the vocal folds. A recent study has a detailed presentation of OCT of the vocal folds. Till now, we had no biopsies of the arytenoid regions because they have not been focused upon, even in this study. **Focus has been on the vocal folds with OCT and the difficult construction of a probe for the larynx (1).** In laryngology the mucosa also has other areas of interest than the vocal folds. **When it comes to treatment, especially in benign voice and swallowing disorders in the upper airways also in singers, laryngologists also orientated to pharmacology and genetics, have an interest in documentation diagnosis and treatment effect (11).** As a routine, lactose intolerance, gluten intolerance and mannose binding lectin is checked. These factors are known to affect the mucosal function all over the body and maybe the reason for the difference found between laryngopharyngeal reflux and gastroesophageal reflux.

Discussion

- Till now this has only been possible for the surface of the larynx with high speed films with 4000 pictures per second as the true measure of vocal folds and arytenoid region surface (Fig. 1). Objective findings of laryngeal appearance on OCT images including histology related to cytoplasm, with cellular and molecular events results in arytenoid oedema in the superficial epithelium. OCT also enables visualizing of large and irregular glands as well and expanding blood vessels. A disorganized architecture of the epithelium can be presented together with an increased nuclear to cytoplasm ratio. **Since treatment of many disorders in the larynx are till now documented with only high speed films and subjective complaints – the aspect of – as a minimum – to describe oedema and the disappearance hereof with OCT would be a great step forward.** Differences of the arytenoid area with OCT between various disorders is expected especially of the dramatic effect of laryngeal treatment with fexofenadine and local budesonide inhaler in dystonia patients (2).

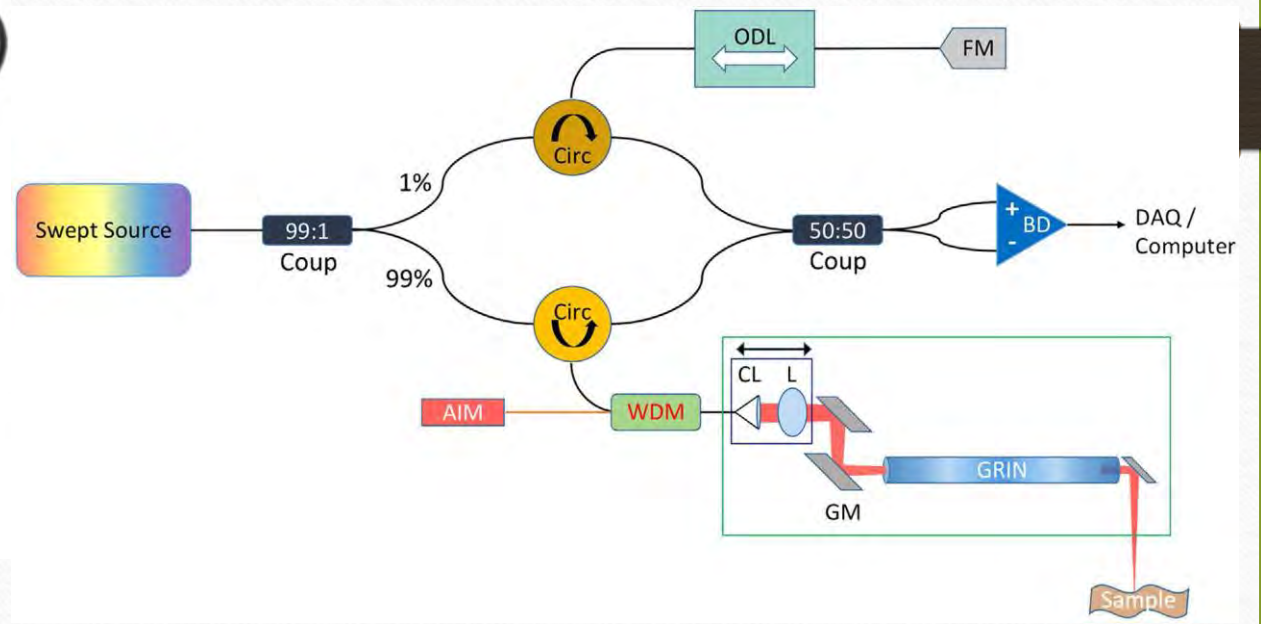
Conclusion

- The optical coherence tomography evaluation of tissue without biopsy has come to stay.
- It is invaluable in ocular and dermatological diagnosis and treatment (1).
- We have earlier made a poster with an overview of most clinical upper airway areas (10). In laryngology focus has been on the vocal folds (1). Based on a more than 10 years long experience of high speed films development, optical coherence tomography of the larynx arytenoid region and not only the vocal folds will be significant to laryngological and related diagnose and treatment.

References

1. Carolin A Coughlan et al. (2016) In vivo cross-sectional imaging of the phonating larynx using longtime Doppler optical coherence tomography. Nature.com/scientific reports 6:22792 DOI: 10.1038/srep22792
- 2a. Pedersen M, Eeg M (2012) Does treatment of the laryngeal mucosa reduce dystonic symptoms? A prospective clinical cohort study of mannose binding lectin and other immunological parameters with diagnostic use of phonation function studies. European Archives of Otorhinolaryngology. May 2012, Vol 269, issue 5, pp 1477-1482.
- 2b. Krzysztof Izdebski et al. (2016) Normal and Abnormal Vocal Folds Kinematics: High Speed Digital Phonoscopy (HSDP), Optical Coherence Tomography (OCT) & Narrow Band Imaging (NBI®). Book. Chapter 13, p.115-124.
3. Pedersen M, Eeg M (2012) Laryngopharyngeal reflux – a randomized clinical controlled trial. Otolaryngology, Omnicis publishing group. SI:004. doi:10.4172/2161-119X
4. Pedersen M, McGlashan J (2012) Surgical versus non-surgical intervention for vocal cord nodules (review). The Cochrane library update Oxford. Wiley publishing.
5. Hopkins C, Yousaf U Pedersen M (2006) Acid reflux treatment for hoarseness (review). The Cochrane library Oxford. Wiley publishing. Issue 2.
6. Lazarow, F.B. et al. (2015) (20059 Intraoperative long range optical coherence tomography as a novel method of imaging the pediatric upper airway before and after adenotonsillectomy. Int J Otorhinolaryngol 79, 63-70, doi: 10.1016/j.ijporl.2014.11.009.
7. Pedersen M (2008) Development of voice in childhood. Ed. Springer.
8. Pedersen M (2014) Future aspects of cellular and molecular research, Advances in Cellular and Molecular
9. Pedersen M (2015) Aspects of resonance. A comparison of high speed films and over tone measures. J health education and development. 3:3 pp.
10. Pedersen et al. (2014) Optical coherence tomography for studies of the larynx mucosa in the arytenoid regions - a protocol. Poster. XXVII congress of the European Phoniaticians. Moscow. Russia and at the General Assembly of the Danish Society of Otolaryngology, Head and Neck Surgery, Nyborg, Denmark.
11. Pedersen M (2013) Chapter 1.1.18, Genetics, Phoniatics; Voice, Swallowing, Speech, Language, Pediatric Hearing Disorders, European Manual of Medicine, Springer. In press (expected in 2016). Presented in IFOS 2013 by invitation.
- 12. Wong BJ at al. (2016) In vivo cross-sectional imaging of the phonating larynx using long-range Doppler optical coherence tomography, [Sci Rep. 2016 Mar 10;6:22792](#)**

In vivo cross-sectional imaging of the phonating larynx using long-range Doppler optical coherence tomography (2016) Wong BJ



Brian Wong et al. 2016

